

COCCIDIOSIS IN A MALLEEFOWL (*Leipoa ocellata*) (CASE 520.1)

CASE HISTORY

Juvenile male Malleefowl (*Leipoa ocellata*) found weak and listless, and died the same day.

GROSS PATHOLOGY

Body condition: good.
No visible lesions found on post mortem.

HISTOPATHOLOGY

No visible lesions: myocardium, spleen, proventriculus

Brain: There is mild perivascular haemorrhage within the meninges and parenchyma.

Lung: The pulmonary tissues are markedly congested. Some large airways contain luminal mononuclear cells or are lined by mononuclear cells. Bacterial colonies are evident within one aggregate of mononuclear cells.

Liver: There are multiple foci of portal haematopoiesis. Random aggregates of hepatocytes have markedly vacuolated cytoplasm.

Kidney: The renal interstitium bears multiple foci of haematopoiesis.

Small intestine: The intestinal tract is mildly autolytic. Within two sections of intestine the mucosa is intact, but contains large numbers of macrogametocytes, microgametocytes and oocysts. One section of intestine has nearly diffuse caseous necrosis of the mucosa and a transmural non-suppurative cellular infiltrate. Very large numbers of coccidial macrogamonts, microgamonts and oocysts are evident throughout the remnants of mucosa. The intestinal lumen is filled with bacterial colonies and coccidial oocysts.

MORPHOLOGICAL DIAGNOSIS

Segmental subacute necrotic enteritis - Coccidiosis

COMMENTS

The bird suffered extensive necrotic enteritis, which was most certainly caused by the extremely large burden of coccidia. Mild changes within the lung and liver indicate that the bird may have been bacteraemic prior to death. Bacteria may have accessed the circulatory system through the necrotic mucosa.

Coccidial infections are commonly subclinical, however periodically (especially under conditions of high

contamination or stress) massive replication and release of oocysts can cause severe damage to the intestinal mucosa.

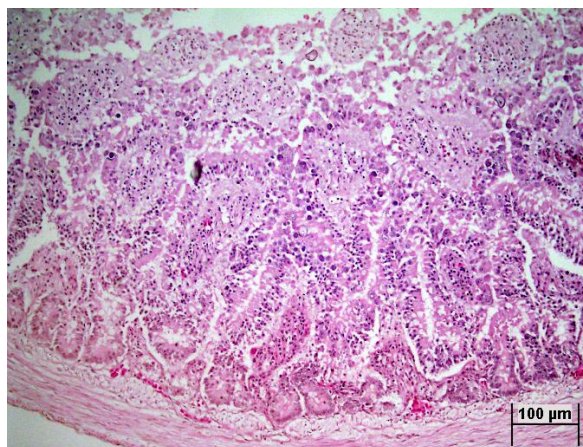


Fig 1. Small intestine, mild autolysis. Note basophilic coccidial structures. H&E 20x

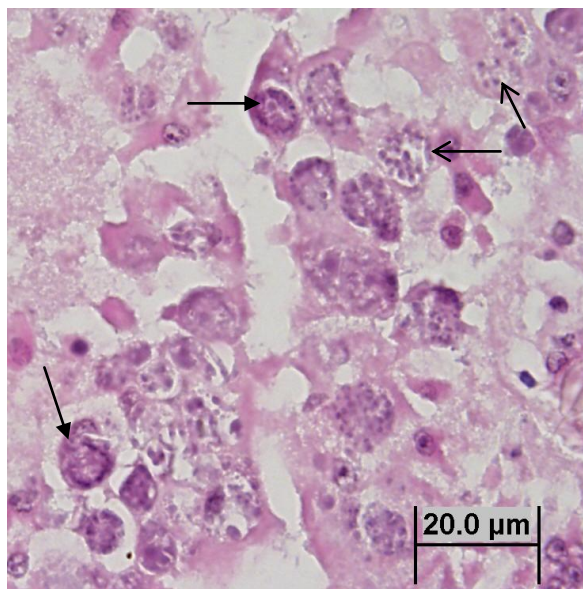


Fig 2. Microgametocytes (open arrows) and macrogametocytes (closed arrows). Small intestine, H&E 100x

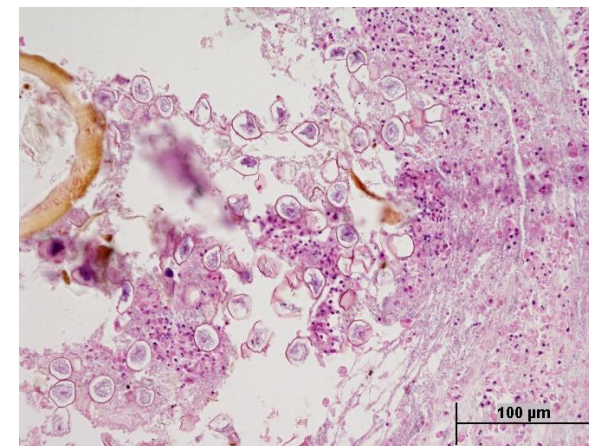


Fig 3. Coccidial oocysts in lumen of small intestine. Note necrosis and loss of intestinal mucosa. H&E 40x

REFERENCES

- RAMAN, M. JAYATHANGARAJ, M. G. RAJESH, K. C. RAJAVELU, G. Subclinical coccidiosis in feral pigeons. *Indian J Vet Med.* 2000. 20(2): 95. 6.
- BROWN, M. A. BALL, S. J. HOLMAN, D. The periodicity of isosporan oocyst discharge in the greenfinch (*Carduelis chloris*). *J Nat Hist.* 2001. 35(7): 945-948.
- NOVILLA, M. N. CARPENTER, J. W. JEFFERS, T. K. WHITE, S. L. Pulmonary lesions in disseminated visceral coccidiosis of sandhill and whooping cranes. *J Wildl Dis.* 1989. 25(4): 527-533.
- HOLZ, P. H. Disseminated granulomas caused by protozoan megaloschizonts in superb lyrebirds (*Menura novaehollandiae*). *AVJ.* 1997. 75(9): 672-673.
- GOMIS, S. DIDIUK, A. B. NEUFELD, J. WOBESER, G. Renal coccidiosis and other parasitologic conditions in lesser snow goose goslings at Tha-anne River, west coast Hudson Bay. *J Wildl Dis.* 1996. 32(3): 498-504.
- RANUM, A. WHARTON, D. A. Helminth and protozoan parasites of the alimentary tract of the yellow-eyed penguin (*Megadyptes antipodes*). *NZ J Zool.* 1996. 23(1): 83-87.