

MITE (*Cnemidocoptes sp.*) INFESTATION IN A PIED CURRAWONG (*Strepera versicolor*) (CASE 969.1)

CASE HISTORY

Adult male pied currawong (*Strepera versicolor*) found caught in fence with lumps on feet.

GROSS PATHOLOGY

External findings: Very thick, proliferative crusts diffusely coat the skin of the tarsi and feet. The bird is palpably emaciated. A breast blister is evident along the sternum.

Hydration: poor, **Fat deposits:** absent, **Muscle mass:** poor

Internal findings: No significant findings.

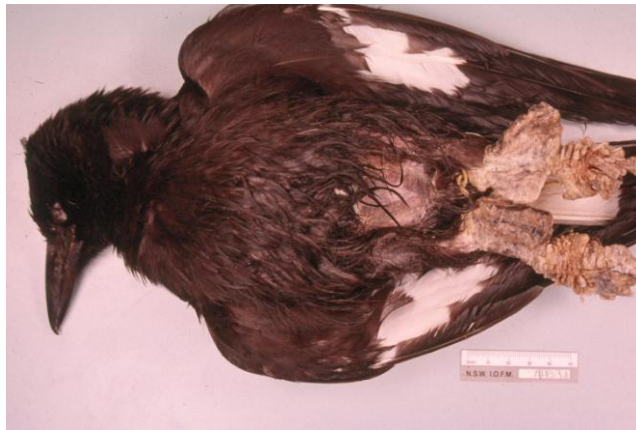

Fig 1. Pied currawong with gross lesions.

HISTOPATHOLOGY

The sample consists of a large wedge biopsy taken from the plantar surface of the left foot.

The keratin layer is markedly thickened and contains many lacunae (Fig 1). These lacunae contain cross sections of arthropod parasites, parasite ova and occasionally bacterial colonies. Mites are present within both the superficial and deep keratin. Clusters of degenerating cellular debris are multifocally evident within the keratin layers. Within one section of the sample, mites are present within lacunae adjacent to attenuated and necrotic epithelium. The dermis contains a variable inflammatory reaction ranging from mild oedema and scattered granulocytes, to a more severe perivascular mononuclear cell infiltrate containing scattered granulocytes. Small numbers of leukocytes are scattered throughout the epithelium and keratin.

Case interpretation: Karrie Rose. Photography and case construction: Damien Higgins

PARASITOLOGY

Skin - KOH preparation: large numbers of mites are evident.

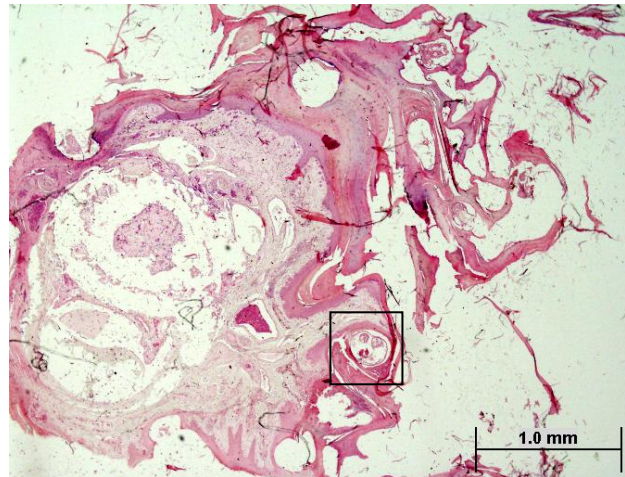


Fig 2. Biopsy, plantar surface of foot. Note hyperkeratosis and section of mite within lacuna in stratum corneum (inset). H&E 4x

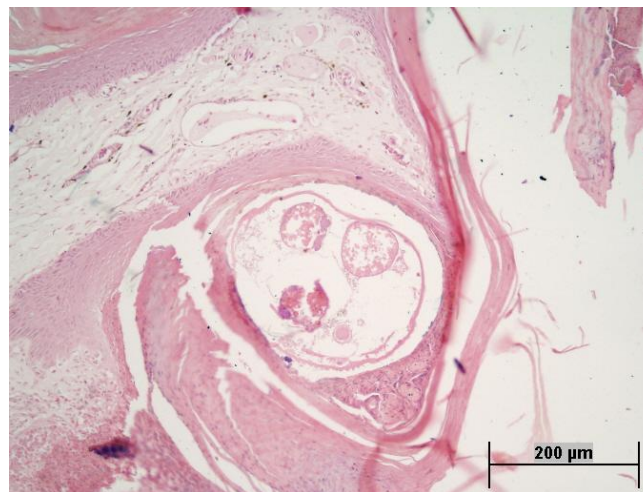


Fig 3. Cross section of mite in stratum corneum (see inset Fig 2). Note cuticle and internal organs. H&E 20x

MORPHOLOGICAL DIAGNOSIS

Euthanasia

Marked extensive hyperkeratosis - tarsal and pedal skin - *Cnemidocoptes sp.*

Focal breast blister

COMMENTS

The bird was very thin, debilitated and suffering from a breast blister due to the hyperkeratotic lesions on both feet. The hyperkeratotic skin lesions are due to severe infestation with *Cnemidocoptes* species.

REFERENCES

JAENESCH, SM, RAIDAL SR AND HOBBS R. (2003) *Cnemidocoptes intermedius* in a wild currawong (*Strepera graculina*). Australian Veterinary Journal 81: 411.