

YOLK PERITONITIS IN A WONGA PIGEON (*Leucosarcia melanoleuca*) (CASE 1485.1)

CASE HISTORY

Adult female Wonga pigeon (*Leucosarcia melanoleuca*), found very lethargic. Delivered to vet, but died en route.

GROSS PATHOLOGY

External findings: No significant lesions.

Hydration: dehydrated

Muscle mass: good

Fat deposits: absent

Internal findings: The serosal surfaces of the caudal coelomic cavity appear oedematous and coated with a tan, granular exudate. The oviduct is markedly distended with luminal pink, thick liquid. The oviduct is thin walled and the mucosa is rugose and granular. The liver is large and friable. The tissues are moderately autolytic. The GIT contains ingesta. The ovary is composed of many regressing ova.

HISTOPATHOLOGY

Lesions are not evident within the following tissues: proventriculus, oesophagus, trachea, brain, heart, kidney, ovary, oviduct, adrenal gland, spleen

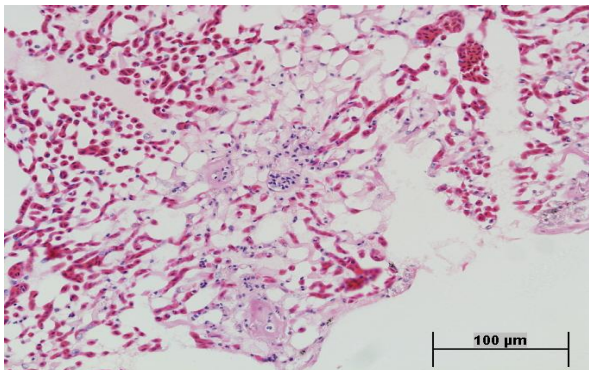


Fig 1. Lung. H&E 40x

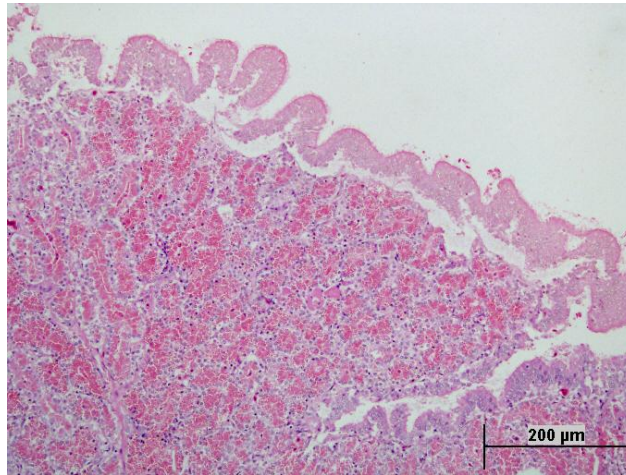


Fig 2. Oviduct. Note normal mucosa and submucosa. H&E 20x

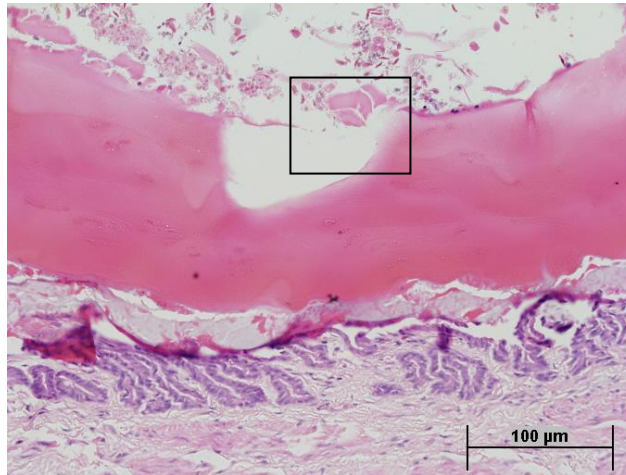


Fig 3. Proximal oviduct

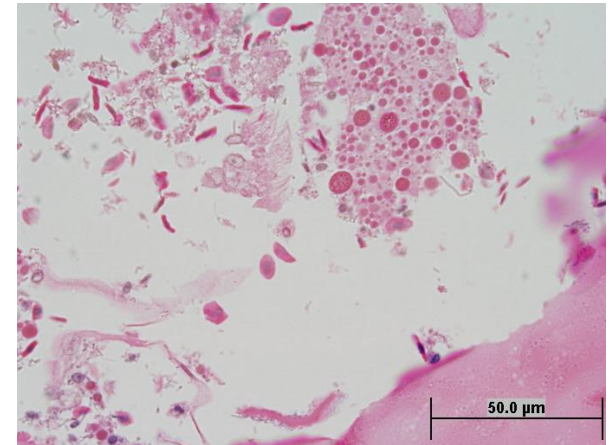


Fig 4. Lumen of proximal oviduct (see inset Fig 3).

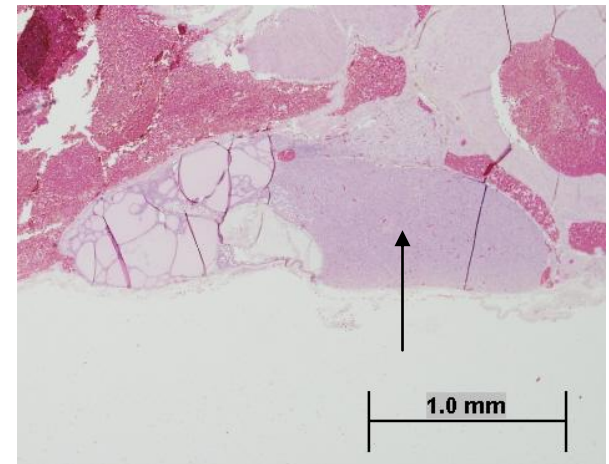


Fig 5. Unidentified tissue.

Tasks: describe the sections provided. What is the unidentified tissue in Fig 5? How might this finding relate to this case and the bird's cagemates?

HISTOPATHOLOGY

The serosal surfaces throughout the coelomic cavity are coated with a very thick layer of exudate. This exudate is composed of eosinophilic amorphous material, erythrocytes, large macrophages, heterophils, magenta globules (yolk protein), and small numbers of bacterial colonies (Fig 3, 4). Macrophages within the exudate have phagocytosed magenta globules, bacteria, erythrocytes and other cells. This exudate is most severe surrounding the ovary and adrenal gland, and a similar infiltrate is present within the ovarian adventitia.

Lung: There is moderate perivascular and interlobular oedema within the pulmonary parenchyma. Multiple small thrombi are evident within smaller pulmonary blood vessels (Fig 1).

Ovary: The ovary contains many large, regressing ova.

Oviduct: The oviduct lumen contains luminal macrophages and bacteria, but the mucosa itself appears quite normal. The proximal oviduct contains free proteinacious material (probably yolk). The underlying mucosa appears normal. There is growth of bacteria (predominantly rods) within the material, and some macrophages containing bacteria and eosinophilic material (Fig 3, 4).

BACTERIOLOGY

Oviduct: 3+ *Escherichia coli*

Liver: 1+ Gram negative rod

MORPHOLOGICAL DIAGNOSIS

Marked septic yolk peritonitis - *E. coli*

Marked intestinal nematodiasis

Parathyroid gland hyperplasia

COMMENTS

The bird had a markedly dilated oviduct upon gross post mortem examination. It is possible that the oviduct became obstructed secondary to the peritoneal inflammation. The bird had marked intestinal nematodiasis and parathyroid gland hyperplasia (Fig 5: a large endocrine gland is visible to the right of the follicles of the thyroid [arrow]. This gland is the parathyroid and is larger than normal. The parathyroid secretes parathormone, and can become hyperplastic in response to persistently low blood calcium), indicating that

the parasite control program and diet should be reviewed for this aviary.

REFERENCES

Yolk peritonitis

TANGREDI BP, KROOK LP. Nutritional secondary hyperparathyroidism in free-living fledgling American crows (*Corvus brachyrhynchos brachyrhynchos*). *J Zoo Wildl Med.* 1999 30(1): 94-99.

Case interpretation: Karrie Rose. Photography and case construction: Damien Higgins