

# CRYPTOSPORIDIOSIS IN A CORN SNAKE (*Elaphe guttata*) (CASE 616.1)

## CASE HISTORY

Juvenile corn snake (*Elaphe guttata*) seized at Mascot Customs Control with 16 other snakes. Euthanased by order.

## GROSS PATHOLOGY

No visible lesions.

## HISTOPATHOLOGY

Lesions are not evident within the following tissues: skin, muscle, brain, salivary gland, kidney, liver, myocardium.

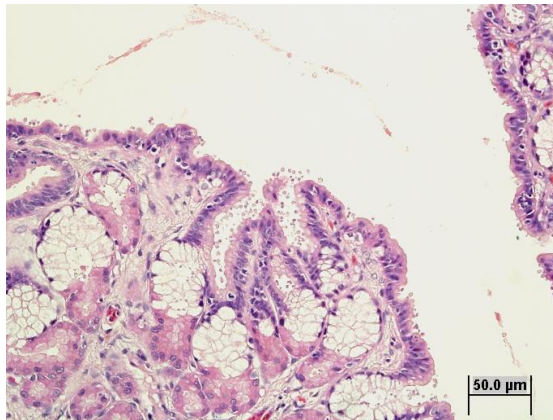


Fig 1. Gastric mucosa. H & E 40x

The following observations are notable:

**Stomach:** The gastric mucosal surface bears many small round bodies which are attached to the epithelial cells by short stalks (Figs 1, 2, 3). The round bodies are moderately refractile and ZN positive. There are occasional basophilic intranuclear inclusion bodies within the gastric mucosal cells (Fig 4). The chromatin of affected cells is peripheralised and the nuclei may be mildly enlarged.

## MORPHOLOGICAL DIAGNOSIS

Euthanasia  
Gastric cryptosporidiosis  
Intranuclear inclusion bodies - gastric mucosa

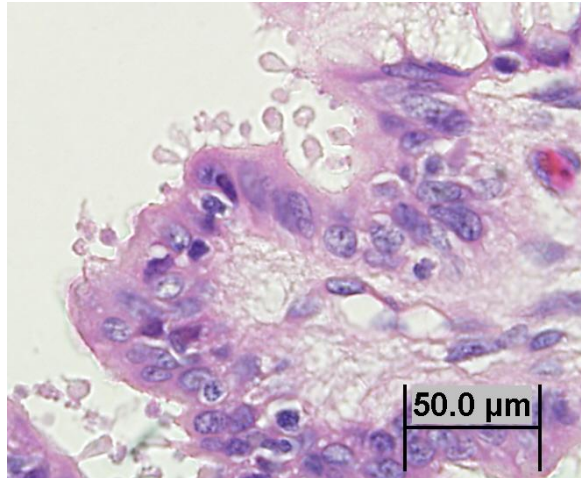


Fig 2. Cryptosporidia, gastric mucosa. H & E 100x

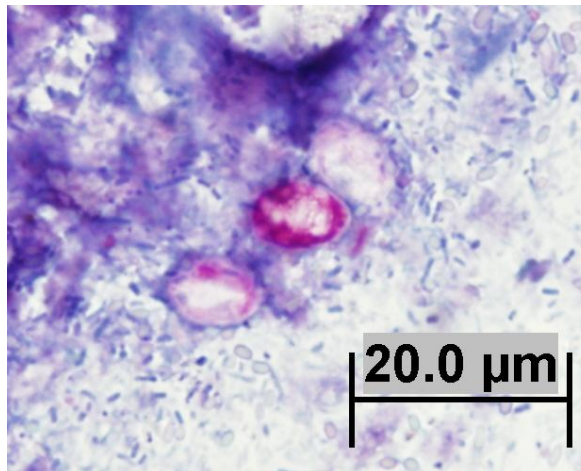


Fig 3. Acid fast cryptosporidial oocysts. Modified Zeihl-Neelsen stain. 100x

## COMMENTS

The snake has a severe gastric infection with *Cryptosporidia*. Intranuclear inclusion bodies evident within the gastric mucosa may represent viral infection, but viral culture of liver and kidney did not reveal the presence of any viral agents. Immunohistochemistry upon these tissues was also negative for reaction to a fish iridovirus.

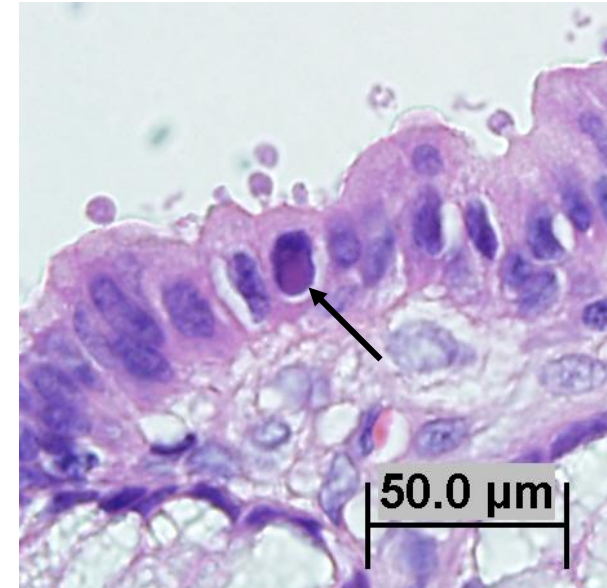


Fig 4. Intranuclear inclusion (arrow), gastric mucosa. H&E 100x

## REFERENCES

<http://www.ksu.edu/parasitology/basicbio>

HASSL, A.; BENYR, G. Hygienic evaluation of terraria inhabited by amphibians and reptiles: cryptosporidia, free-living amebas, salmonella. Wiener Klinische Wochenschrift: 2003. 115: Suppl.3, 68-71.

MCKENZIE, R. A.; GREEN, P. E.; HARTLEY, W. J.; POLLITT, C. C.E *Cryptosporidium* in a red-bellied black snake (*Pseudechis porphyriacus*). Australian Veterinary Journal. 1978. 54: 7, 365-366.

<http://www.cdc.gov/parasites/crypto/>

XIAO, L, et al. Genetic diversity of *Cryptosporidium* spp. in captive reptiles. Applied Environmental Microbiology, 2004, 70(2): 891-899.